

Ultrasound guided injections of Platelets Rich Plasma for muscle injury in professional athletes. Comparative study.

Rostyslav Bubnov¹, Viacheslav Yevseenko², Igor Semenov²

¹ Centre of Ultrasound Diagnostics and Interventional Sonography, ² Centre for Orthopedics, Traumatology and Sport medicine, Clinical Hospital "Pheophania" of State Affairs Department, Kyiv, Ukraine

Abstract

Aim: Professional athletes require faster recovery after trauma. The aim of our study was to evaluate the efficacy of ultrasound guided platelets rich plasma (PRP) treatment for acute muscle injury comparing with traditional conservative therapy. **Materials and methods:** Thirty consecutive men (mean age 24 years old) professional athletes with acute local muscle injury were enrolled. All patients underwent US and sonoelastography examination. Patients were randomly assigned to 2 groups: group A received targeted PRP injection under US guidance and additionally conservative treatment and group B received conventional conservative treatment only. The pain was assessed according to visual analogue scale (0 to 10), muscle function according to pain on resisted flexion or strength, and range of motion. Both groups were further evaluated in the days 1, 7, 14, 21, and 28 after treatment starting. US criteria for regeneration were considered to be the disappearance of hypoechoic areas of muscle damage, fibrous tissue more stiff on sonoelastography, and neovascularity appearances. **Results:** The pain relief was more important in group A compared to group B starting from day 1 and continuing in the next 3 evaluation sessions ($p < 0.05$). At the end of observation (28 day), 93 % of pain regression was declared by patients in group A vs 80 % of regression of pain in group B ($p > 0.05$). Assessing the physical evolution in the 7th and 14th days significant changes in strength ($p < 0.05$) and range of motion ($p < 0.05$) for PRP treatment group was observed. After 28 days no significant differences between groups were observed concerning the pain on resisted flexion and strength ($p > 0.05$) but the range of movement improved better in group A compared with group B ($p < 0.05$). Subjective global function scores improved significantly in group A compared with group B on the 28th day ($p < 0.05$). The mean time for the physical recovery movement volume and the ability to practice sport was 10 ± 1.2 days in group A and 22 ± 1.5 days in group B. **Conclusions:** Injections of PRP under ultrasound guidance had significantly higher level of pain relief, physical recovery, and faster regeneration compared with conventional conservative treatment in acute muscle trauma in professional athletes. **Keywords:** muscle trauma, athletes, ultrasound, platelets rich plasma,

Introduction

According to the World Health Organization (WHO), musculoskeletal injuries are the most common cause of severe long-term pain and physical disability, and affect hundreds of millions of people worldwide [1]. Introduction of the platelets rich plasma (PRP) therapy, prepared from autoblood containing its own growth factors, is con-

sidered to be a promising solution to accelerate the healing process of the injured soft tissue [1-5]. This need is especially important in professional athletes who require a faster recovery after trauma. PRP contains growth factors and bioactive proteins that influence the healing of tendons, ligaments, muscles, and bones.

In 1981 Antoniades [2] identified two types of platelet-derived growth factors (PDGF I and II). These growth factors are small proteins that stimulate cellular proliferation, migration, differentiation, and matrix synthesis, influence the metabolism of chondrocytes, chondrogenesis, and improve the healing of tendons and muscles *in vivo*.

Musculoskeletal ultrasound (US) provides clinicians with sufficient data about the muscle injury [3,4]. Also,

Received 05.02.2013 Accepted 22.03.2013

Med Ultrason

2013, Vol. 15, No 2, 101-105

Corresponding author: Rostyslav Bubnov

Clinical Hospital "Pheophania"

21 Zabolotny str, 03680 Kyiv, Ukraine

Tel. +380442596237, Fax +380442596959

E-mail: rostbubnov@gmail.com

US technique is the most effective method for guiding the puncture of soft tissues [5,6].

Currently, most studies on PRP therapy are anecdotal, nonrandomized, or involve insufficient sample sizes and are underpowered [6]. Recently, there is emerging literature on the beneficial effects of PRP for chronic, non-healing tendon injuries including lateral epicondylitis and plantar fasciitis [6-8]. However, at present, there are limited studies documenting the safety and efficacy of PRP use in degenerative process as e.g., knee osteoarthritis (OA). There are publications about PRP administration under ultrasound guidance for the treatment of lateral epicondylitis [9-11] or treatment of adductor longus muscle damage [12,13]. Sanchez et al reported the use of platelet growth factors for the treatment of articular cartilage avulsion [14]. Also Sanchez et al compared PRP and hyaluron acid administration into osteoarthritic knees and showed better pain relief with PRP [15].

However, little has been published about the use of growth factors in acute muscle damage. Recent studies indicate the feasibility of the combination of dry-needling and the introduction of growth factors as an effective conservative treatment tendinopathies [16].

Autologous PRP has emerged as a treatment option for tendinopathies and chronic wounds. In addition to the release of growth factors, PRP also promotes concentrated anti-inflammatory signals including interleukin-1ra, which has been a focus of emerging treatments for osteoarthritis [17].

The aim of our study was to evaluate the efficacy of ultrasound guided PRP treatment for acute muscle injury compared with traditional conservative therapies in professional athletes.

Material and methods

Thirty consecutive men patients, mean age 24 years old, professional athletes, with acute local muscle injury, diagnosed clinically and confirmed by ultrasonography were enrolled. All patients underwent US examination using 12 MHz linear probes of US machines Sonosite Turbo and Hitachi HV 900 with sonoelastography function in the day of injuries.

Muscle injuries were visualized as areas of alteration in the normal structure of the muscles, hypoechoic areas, small haematomas, or interruption of the continuity of the muscle fibers. Sonoelastography was used to identify local changes in the muscle elasticity.

Patients were randomly assigned to 2 types of treatment. Patients of group A received targeted PRP injection under US guidance in the lesion and additionally conservative treatment (including immobilization, general physio-

therapy, and anti-inflammatory therapy). Patients in group B received only conventional conservative treatment.

The 2 groups were assessed on the day of presentation, after 24 h (1st day) and in the 7th, 14th, 21th, and 28th days after treatment starting (6 evaluations). The pain was evaluated according to the visual analogue scale data (VAS): 0- no pain, 10- the worst possible pain. Physical assessment consisted of assessing the muscle function according to pain on resisted flexion, strength, and range of motion - extension, pronation, or supination of injured muscle. Patient's self-evaluation consisted of subjective global function scores, using a scale from 0 to 100 (with 100 representing healthy, preinjury function). The US criteria for regeneration of the injured muscle of tissue recurrence were the disappearance of hypoechoic areas of muscle damage, the replacement of the hematoma by fibrous tissue, fibrous tissue more stiff on sonoelastography, and neovascularity appearance.

For the PRP preparation approximately 40 cm³ of the patient's venous blood was collected. The blood was buffered with trisodium citrate and was placed into a centrifuge. After centrifugation, the platelets and plasma were separated from the red and white blood cells. The 2 cm³ plasma fraction located just above the sedimented red blood cells together with the buffy coat fraction, were collected. The PRP was then loaded into a 5-mL syringe with a 22-gauge needle. After US identification of the injury and aspiration of hematomas, the freshly prepared PRP was injected under US control.

The medical Ethics Committee of the Clinical hospital "Pheophania" of State Affairs Department approved the study and written informed consent was obtained from all participants.

Statistical method: The Student t-test was applied to perform the comparison between the groups; the Spearman's rank correlation coefficient R for study relationship between two variables of outcome in both groups was used.

Results

In the thirty patients included in the study, we registered 34 lesions: two patients of group A had thigh and ankle trauma and similarly two patients in group B had same kind of combined trauma of the lower limb (table I).

Table I. Types of trauma founded in the study groups.

Place of injury	Group A	Group B
thigh trauma	10	8
foot and ankle trauma	5	5
shoulder trauma	2	4
Total	17	17

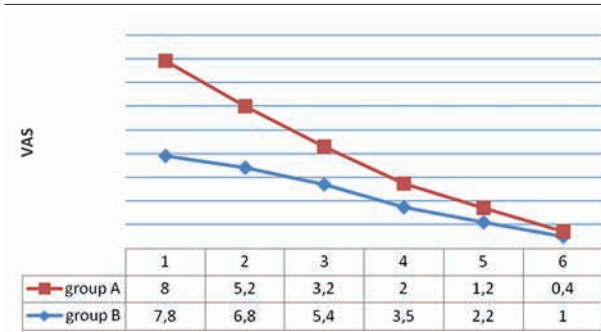


Fig 1. Quantification of the pain using VAS during the 6 evaluation sessions

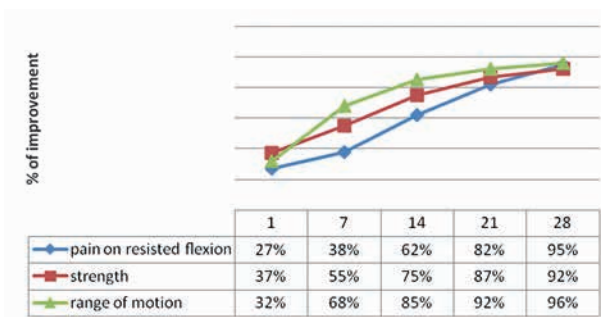


Fig 2. Physical assessment evolution in group A (days 1 to 28)

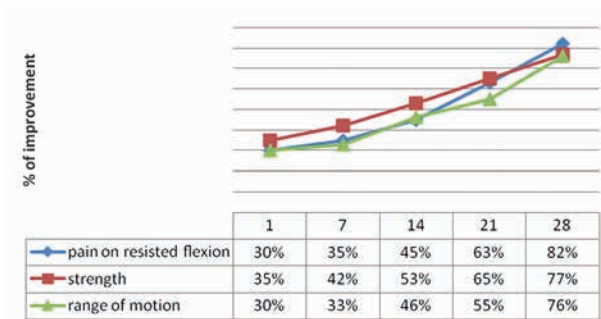


Fig 3. Physical assessment evolution in group B (days 1 to 28)

Pain relief (fig 1) was observed starting from day 1, 24 hours after procedure: 28% pain relief according to VAS scores were seen in group A compared to 10% in group B ($p < 0.05$); the same statistical signification in pain reduction was observed in the next 3 evaluation session ($p < 0.05$). After 28 days, 93 % of pain regression was declared by patients in group A vs 80 % of regression of pain in group B. The difference was not statistically significant ($p > 0.05$).

The physical assessment evolution is presented in fig 2 for group A and in fig 3 for group B. On the 1st day no significant differences between groups was observed concerning the muscle function (pain on resisted flexion,

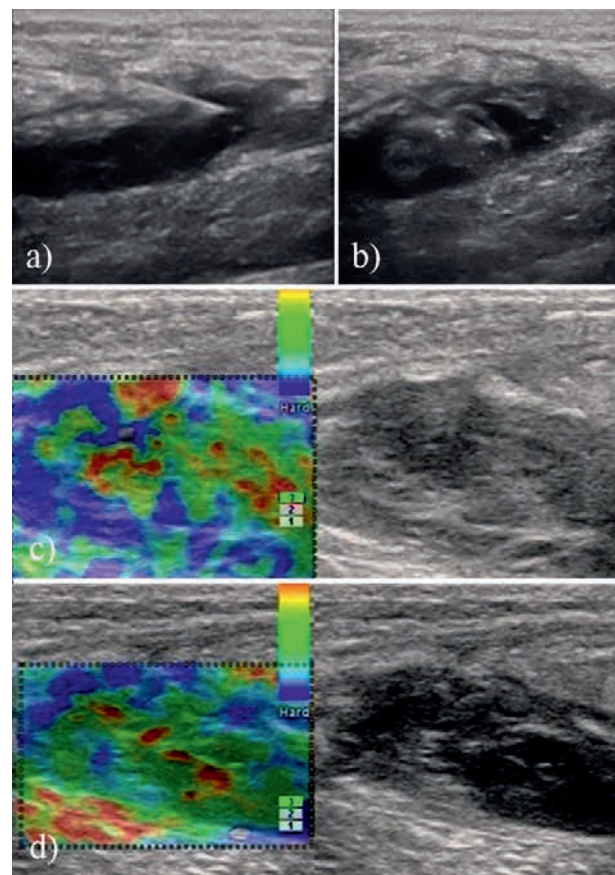


Fig 4. A professional football player, 22 years old. Postrauma hematoma of the left thigh: a) hematoma aspiration under ultrasound guidance, longitudinal scan; b) PRP administration; c) sonoelastography on 7th day – the hematoma was replaced by heterogeneous tissue with a predominance of dense component corresponding to fibrosis; d) sonoelastography on 14th day- the elasticity of the regenerating tissue is growing comparing with 7th day examination

strength, and range of motion, all $p > 0.05$). On the 7th day significant changes in strength ($p < 0.05$) and range of motion ($p < 0.05$) for PRP treatment group were found. After 14 days the improvement in physical assessment in group A group was significantly superior according to all parameters ($p < 0.05$). After 28 days the pain on resisted flexion and strength were quite similar in the two groups ($p > 0.05$) but the range of motion improved, better in PRP treatment group compared with standard treated patients ($p < 0.05$).

Subjective global function scores improved from 55 (group A) and 53 (group B) at baseline to 92 (group A) and 74 (group B) respectively in 28th day ($p < 0.05$).

Regenerative process was diagnosed on ultrasonography at 7 days after treatment starting 3 patients (20 %) from group A compared to 0 patients in group B ($p < 0.05$) and on the 14th day in 12 patients from group A (80 %) compared with 3 patients (20 %) from group B, ($p < 0.01$). After 21 days all the patients from group A and 11 patients from group B had regenerative changes on ultrasonography ($p > 0.05$). On the 28th day the regenerative processes were identified in all patients.

We found a strong correlation in assessing regression between regenerative process and all parameters of physical assessment were observed (the Spearman's rank correlation coefficient r was 0.94 for all measurements).

The mean time for the physical recovery movement volume and the ability to practice sport was 10 ± 1.2 days in group A and 22 ± 1.5 days in group B.

In figure 4 we illustrated one of the cases included in group A.

Discussion

Our findings confirm that the pain relief was faster in group A after PRP treatment; however, difference with traditional therapy was insignificant in the late outcome. Also we observed significant changes in strength, range of motion, and pain on resisted flexion that were significantly higher after 1-2 weeks of PRP treatment. Range of motion recovery was registered as the most beneficial result. Assessing the regenerative process we found significantly better results from the early stages in the PRP treated group, which is crucial for the athletes' recovery. A strong correlation between ultrasound and clinic findings was observed.

Thus, the early pain relief lead us to conclude that PRP therapy is effective for pain treatment. In combination with effective physical restoration and high subjective global function scores it can initiate an early rehabilitation and decrease the mean time of treatment.

We have not found published comparative studies between standard conservative treatment and PRP administration in acute muscle injury, but faster pain relief was reported by many authors after steroid therapy [10,18,19]. Comparing the data dedicated to PRP and steroid administration [10] we assume that steroid injections may provide symptomatic relief, but no evidence was provided that steroids promote healing. Steroids decrease the inflammatory process (but this is not always present in injuries) and have also specific side effects. Moreover, in the study of Gosens et al comparing PRP versus corticosteroid injection for lateral epicondylitis treatment, the patients from the PRP group were more often treated successfully compared with the corticosteroid group. The

PRP group had worse DASH scores before treatment and better ones after 26 weeks of the initial treatment [18].

Preliminary results have shown that PRP treatment led to a significantly better outcome than hyaluronic acid administration for the management of osteochondral lesions of the talus [19].

PRP regenerative activity can be explained due to the secretion from the activated platelets aggregated into a clot of a variety of cytokines including adhesive proteins and growth factors [4,20-23]. These cytokines play important roles in cell proliferation, chemotaxis, cell differentiation, and angiogenesis. Also the cytokines are capable of inducing an expression of new genes [24] and have antibacterial properties [25] that may also improve the results of treatment. The PRP could be potentially used in any part of an injured muscle, tendon, or ligament: shoulder pain, rotator cuff tear, knee pain or tendon tears, knee meniscus tear, foot pain, plantar fasciitis, hip pain, lower back pain, etc. In arthritis or osteoarthritis the treatment using PRP has not yet been considered due to the effect of the growth factors on the cartilage loss, subchondral bone deterioration, alterations in synovium, ligaments, capsule, or menisci [6,22]. The majority of recently proposed therapeutic modalities for OA has the foundation of attempting to address the cytokine imbalance [6-12,20-23].

Limitations of the study

The main limitations of the study are the small number of patients/lesions and the lack of the double blinded protocol.

Conclusions

Injections of PRP under ultrasound guidance had significantly higher level of pain relief, physical recovery, and faster regeneration compared with conventional conservative treatment in acute muscle trauma of professional athletes.

Conflict of interest: none

Acknowledgment

We acknowledge Prof. Igor Zazirny for his kind advices in study design.

References

1. Woolf AD, Pfleger B. Burden of major musculoskeletal conditions. *Bull World Health Organ* 2003; 81: 646-656.
2. Antoniadou HN. Human platelet-derived growth factor (PDGF): purification of PDGF-I and PDGF-II and sepa-

- ration of their reduced subunits. *Proc Natl Acad Sci U S A* 1981; 78: 7314-7317.
3. Bubnov RV. The use of trigger point “dry” needling under ultrasound guidance for the treatment of myofascial pain (technological innovation and literature review). *Lik Sprava* 2010; (5-6): 56-64.
 4. Bubnov RV. Evidence-based pain management: is the concept of integrative medicine applicable? *EPMA J* 2012; 3: 13.
 5. Micu MC, Bogdan GD, Fodor D. Steroid injection for hip osteoarthritis: efficacy under ultrasound guidance. *Rheumatology (Oxford)* 2010; 49: 1490-1494.
 6. Sampson S, Gerhardt M, Mandelbaum B. Platelet rich plasma injection grafts for musculoskeletal injuries: A review. *Curr Rev Musculoskelet Med* 2008; 1: 165-174.
 7. Mishra A, Pavelko T. Treatment of chronic elbow tendinosis with buffered platelet-rich plasma. *Am J Sports Med* 2006; 34: 1774-1778.
 8. Barrett S, Erredge S. Growth factors for chronic plantar fasciitis. *Podiatry Today* 2004; 17: 37-42.
 9. Connell DA, Ali KE, Ahmad M, Lambert S, Corbett S, Curtis M. Ultrasound-guided autologous blood injection for tennis elbow. *Skeletal Radiol* 2006; 35: 371-377.
 10. Peerbooms JC, Sluimer J, Bruijn DJ, Gosens T. Positive effect of an autologous platelet concentrate in lateral epicondylitis in a double-blind randomized controlled trial: platelet-rich plasma versus corticosteroid injection with a 1-year follow-up. *Am J Sports Med* 2010; 38: 255-262.
 11. Taylor MA, Norman TL, Clovis NB, Blaha JD. The response of rabbit patellar tendons after autologous blood injection. *Med Sci Sports Exerc* 2002; 34: 70-73.
 12. Loo WL, Lee DY, Soon MY. Plasma rich in growth factors to treat adductor longus tear. *Ann Acad Med Singapore* 2009; 38: 733-734.
 13. Rizio L 3rd, Salvo JP, Schürhoff MR, Uribe JW. Adductor longus rupture in professional football players: acute repair with suture anchors: a report of two cases. *Am J Sports Med* 2004; 32: 243-245.
 14. Sanchez M, Azofra J, Anitua E, et al. Plasma rich in growth factors to treat an articular cartilage avulsion: a case report. *Med Sci Sports Exerc* 2003; 35: 1648-1652.
 15. Sanchez M, Anitua E, Azofra J, Aguirre I, Andia I. Intra-articular injection of an autologous preparation rich in growth factors for the treatment of knee OA: a retrospective cohort study. *Clin Exp Rheumatol* 2008; 26: 910-913.
 16. Connell D. Autologous blood injections for the treatment of tendinopathy. *Med Sci Tennis* 2007; 12: 26-27.
 17. Sampson S., Reed M., Silvers H., Meng M., Mandelbaum B. Injection of platelet-rich plasma in patients with primary and secondary knee osteoarthritis: a pilot study. *Am J Phys Med Rehabil* 2010; 89: 961-969.
 18. Gosens T, Peerbooms JC, van Laar W, den Oudsten BL. Ongoing positive effect of platelet-rich plasma versus corticosteroid injection in lateral epicondylitis: a double-blind randomized controlled trial with 2-year follow-up. *Am J Sports Med* 2011; 39: 1200-1208.
 19. Mei-Dan O, Carmont MR, Laver L, Mann G, Maffulli N, Nyska M. Platelet-rich plasma or hyaluronate in the management of osteochondral lesions of the talus. *Am J Sports Med* 2012; 40: 534-541.
 20. Johnson GL, Vaillancourt RR. Sequential protein kinase reactions controlling cell growth and differentiation. *Curr Opin Cell Biol* 1994; 6: 230-238.
 21. Foster TE, Puskas BL, Mandelbaum BR, Gerhardt MB, Rodeo SA. Platelet-rich plasma: from basic science to clinical applications. *Am J Sports Med* 2009; 37: 2259-2272.
 22. Evans CH. Novel biological approaches to the intra-articular treatment of osteoarthritis. *BioDrugs* 2005; 19: 355-362.
 23. Iqbal I, Fleischmann R. Treatment of osteoarthritis with anakinra. *Curr Rheumatol Rep* 2007; 9: 31-35.
 24. Banes AJ, G.Horesovsky G, Larson C, et al. Mechanical load stimulates expression of novel genes in vivo and in vitro in avian flexor tendon cells. *Osteoarthritis Cartilage* 1999; 7: 141-153.
 25. Bielecki TM, Gazdzik TS, Arendt J, Szczepanski T, Król W, Wielkoszynski T. Antibacterial effect of autologous platelet gel enriched with growth factors and other active substances: an in vitro study. *J Bone Joint Surg Br* 2007; 89: 417-420.